Journal of Orthopaedic & Sports Physical Therapy
Official Publication of the Orthopaedic and Sports Physical Therapy Sections of the American Physical Therapy Association

CLINICAL COMMENTARY

Patella Fractures Associated With Accelerated ACL Rehabilitation in Patients With Autogenous Patella Tendon Reconstructions

Bruce Brownstein, MBA, PT [1]
Shaw Bronner, MS, PT, OCS [2]

Patella fracture is a recognized complication of ACL reconstruction with an autogenous patella tendon graft. Typically, fracture occurs as a result of a fall. The incidence of fracture is ~0.5%. Accelerated rehabilitation protocols can place stress on the patella, especially in the initial stages of recovery. Therapists are reminded to observe constraints placed on patients by biological tissues, recovering neuromuscular status, and previous level of conditioning. Rehabilitation protocols should be revised according to these factors.

Key Words: *anterior cruciate ligament, biomechanics, rehabilitation, knee*

[1] *Co-Director, SOAR Research, 51 West 81st Street, New York, NY 10024*
[2] *Co-Director, SOAR Research, New York, NY; Coordinator, HealthSouth Sports Medicine and Rehabilitation Center, New York, NY*

The trend in rehabilitation of patients following anterior cruciate ligament (ACL) reconstruction over the past few years has been to "accelerate" the rehabilitation protocol in order to reduce the time to return to full activity. This type of protocol has been reported by several authors (5,11,13, 18). They report potential return to function in a matter of a few months, almost half the time of "traditional" protocols. The shortening of the rehabilitation process has been enabled by advances in surgical techniques, experience with professional athletes, greater understanding of the rehabilitation demands, managed care demands, etc. This trend has been progressing with consideration of the biologic healing constraints of some, but not all, of the healing tissues (7, 17). Additionally, the status of the neuromuscular control mechanisms is almost never known. These mechanisms include the control of muscle stiffness, monitoring of mechanical variables within the limb, and the production and control of coordinated, functional movement.

Arthroscopic-assisted or endoscopic ACL reconstruction using the patella tendon requires removal of a patella bone block for graft fixation purposes (4,10). Bone block removal leaves a palpable defect in the patella, which rarely shows radiographic evidence of new bone formation. The bone block removal raises the maximum stress in the patella, leaving it at risk (6).

In the past year, two patients have been referred to our clinic after a fracture of the patella following ACL reconstruction. Both fractures occurred while participating in an accelerated post-ACL reconstruction rehabilitation program. Both procedures were performed by experienced surgeons. A third patient also fractured his patella during a fall with rapid flexion of the knee. This mechanism has been reported as a usual cause in post-ACL patellar fracture. That case is not included for description here.

The purpose of this report is to alert practitioners to the possibility of patella fracture when "accelerated" protocols are used without consideration of the healing tissue, patient's preoperative condition, neuromuscular status, and appropriate goals of rehabilitation for any given patient with a reconstructed ACL. Appropriate goals refers to the functional level to which the patient is attempting to return. The nature and essence of selected training tools used in a rehabilitation protocol should be tailored to the patient's experience, capabilities, and functional requirements, rather than the reverse. In this manner, the therapist can utilize preexisting relationships between a patient's cognitive, motor, and sensory processes (14).

Case Histories

Patient A is a 34-year-old male who underwent surgical reconstruction of his ACL following a ski injury. His operative course was uneventful and he was referred to physical therapy for rehabilitation. His rehabilitation course included the initiation of plyometric exercises at the fourth week of rehabilitation (sixth postoperative week). Plyometric exercises were initiated on a leg press machine using simulated jumps, progressing to

FIGURE 1. *Transverse fracture of the patella following box jumping exercises.*

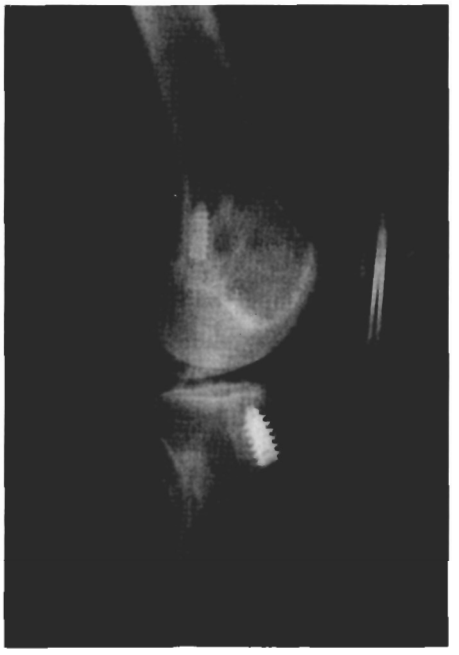

FIGURE 2. *Internal fixation following fracture of patella after box jumping exercises.*

hops within the same week. Full weight-bearing, box jumping activities were begun at rehabilitation week 5. During rehabilitation week 6, the patient was performing these exercises when he felt a pop in his knee with immediate swelling and pain. Subsequent X-rays revealed a transverse fracture of the patella, which was treated with internal fixation and 6 weeks of immobilization (Figures 1 and 2).

Patient B is a 23-year-old female with a long history of patellar instability and chronic ACL deficiency. She underwent a proximal patella realignment but continued to have giving-way episodes. The patient refused reconstruction with an allograft, an autogenous graft from the contralateral knee, or semitendinosus/gracilis graft. Seven months after the proximal realignment was performed, a patellar tendon ACL reconstruction was performed. Immediately after surgery, the patient reported that her knee felt better than it had in the past 10 years. In the fourth week of rehabilitation (sixth postoperative week), she began squat exercise with 50% of her body weight. During the seventh rehabilitation week, squat exercises were increased to 105% of her body weight. The patient reported a cracking sensation while attempting to rise from the squat position. She was told to rest before trying to continue her exercises. Examination by a physician and with X-rays revealed a nondisplaced transverse fracture of the patella which was treated nonoperatively with immobilization. Subsequent arthroscopy showed an intact graft with no meniscal damage.

Postfracture Treatment Protocol

Both patients were referred to our clinic after a 3-week hiatus from physical therapy. Initial emphasis was placed upon recovery of quadriceps function and control, effusion reduction, hip strengthening, and trunk exercises in preparation for functional movement retraining. The functional movement protocol has four phases—Protected Postures, Protected Early Movement, Expanding Movement Boundaries, and Progressive Movement Challenges (1). Each phase is defined in terms of initial patient conditions, direction and type of allowed movements, speed and complexity of movement, type of support conditions (jump, hop, leap, bound, etc.), and motor control demands and goals. General conditioning occurs in conjunction with the functional movement protocol.

After 4 months of treatment, both patients were within 10% of bilateral comparisons on movement skills, reaction time, and balance. Neither patient had episodes of effusion or ACL-related complaints. Patient A began his return to recreational sports without a knee brace and returned to his prereconstruction level of activity without patellofemoral complaints. Patient B had a lifestyle which did not include any athletic activities. She returned to work and full activities of daily living; however, she continued to have mild patellofemoral complaints. These symptoms were present prior to ACL reconstruction. Both patients were evaluated using the modified Noyes questionnaire (20). No preoperative data were available and this evaluation is not presented here.

DISCUSSION

Patella fracture is a rarely reported complication of ACL reconstruction using bone-patella tendon-bone autogenous graft. Carangelo et al noted eight fractures in a series of 1,497 reconstructions, an incidence of 0.53% (2). These fractures resulted from external trauma or a rapid flexion movement while preventing a fall backward. The fractures occurred an average of 7 weeks from surgery. Carangelo et al stated that 50% of the patients had autogenous bone grafting, but did not report whether this was a factor in fracture occurrence. They suggested that the donor site acted as a stress riser leading to failure of the bone. Fractures occurring during a fall may be more traumatic, resulting in more than a simple fracture (Figure 3).



FIGURE 3. *Comminuted fracture of the patella after a fall.*



FIGURE 4. *Thermoplastic stress analysis of a normal patella. (From Friis et al (6), with permission).*

Another reported mechanism of fracture is a twisting maneuver during a golf swing (one reported case), 6 months postoperatively (12). Lambert and Cunningham reported a single fracture in a series of 600+ procedures (10). Christen and Jakob reported six cases of patellar splitting during bone block removal. They also noted three transverse fractures which occurred in the donor site following trauma or hyperflexion while preventing a fall (3). Two of the fractures occurred when the graft was taken from the contralateral knee. All of the postoperative fractures occurred within 2 months of graft removal.

Friis et al (6), using thermoplastic stress analysis and finite element analysis, showed that maximum stress in the patella is significantly increased by removal of a bone block, regardless of the size and shape (Figures 4 and 5). The average stress increase was 170%. The bone block is an integral part of the patella tendon reconstruction and cannot be avoided, making the patella the weak link in rehabilitation after the graft fixation has taken hold. Friis et al, citing a communication from Henning, state that smaller bone blocks and bone grafting may reduce the defect in the patella bone following ACL reconstruction (6).

It is assumed that a goal of rapid return to function was one of the underlying principles of the rehabilitation protocols used in the treatment of these two patients. Both patients followed preset protocols which dictated the postoperative exercise regimen on a week-to-week basis. Patient A is a recreational athlete who occasionally participates in athletic activities such as skiing and softball. Patient B has no athletic history and has a long history of patellofemoral problems and a recent patella surgery prior to reconstruction. Yet both underwent protocols that could easily be applied to a high-level, high performance demand individual.

"Accelerated" rehabilitation takes advantage of improvement in surgical technique, experience in the rehabilitation process, and the motivation and condition of athletically inclined patients. Some protocols call for squatting exercises, plyometric type exercises, and return to running as early as 6–8 weeks of rehabilitation (5,13). There is no mention of the decision-making process based on evaluation of neuromuscular parameters (other than isokinetic testing, a

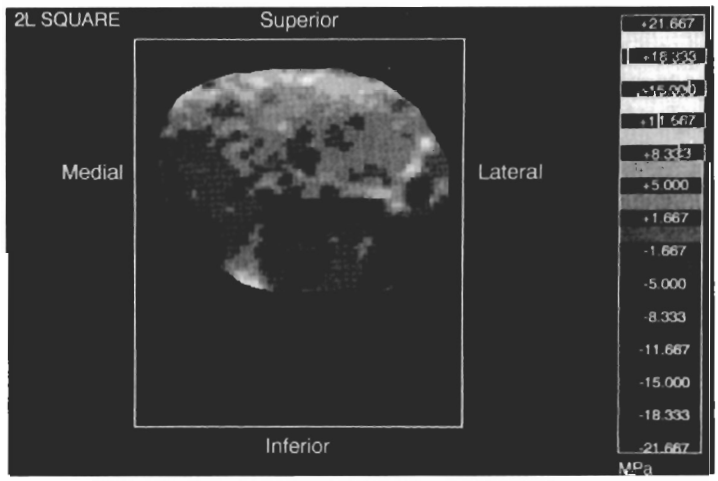

FIGURE 5. *Thermoplastic stress analysis of a patella following bone block removal. (From Friis et al (6), with permission).*

limited indicator of overall function) or healing tissues. Functional rehabilitation requires the restoration of volitional, controlled, and safe movement prior to or simultaneous with the recovery of strength. Pursuing the recovery of strength ahead of other factors in the neuromuscular mix may put excessive forces on the patella, articular structures, and/or the healing graft.

Many rehabilitation programs pursue recovery of knee function in the order of range of motion-strength-functional movement (5,13, 18). We suggest that functional movement be pursued ahead of strength, placing the rehabilitation emphasis on the neuromuscular factors that improve reaction time, promote proximal stability and control of distal components, and restructure the movement patterns which guide function. Excessive joint forces can instigate negative feedback from local receptors which may inhibit, rather than promote, muscle function. Evaluation of the mechanism of nontraumatic fractures of the patella implicates sudden, forceful contractions of the quadriceps as a contributing factor. Neuromuscular training to improve the patient's ability to control and modulate lower extremity muscle activity may mitigate this factor. This type of training should incorporate both feedback and feedforward control activities to integrate sensorimotor deficits created by the rupture of the ACL, removal of the graft, associated effusion, and loss of quadriceps control (8,9). Rehabilitation techniques that generate large joint forces in conjunction with large muscle forces require careful evaluation of the patient prior to initiation (11, 15,16,19).

In some instances, little or no deconditioning occurs postoperatively. Clinically, it can be observed that swelling, decreased muscle girth and contractile control, range of motion, and gait skills are minimally affected in some patients. These patients are able to progress through the range of motion-functional movement-strength cycle faster than the average.

CONCLUSION

The most common complications of post-ACL reconstruction (patella baja, tendinitis, patellofemoral pain) involve the patellar structures. Experience has taught us to encourage early motion, minimize quadriceps inhibition, control effusion, etc. to reduce the morbidity of ACL reconstruction. Therapists have a number of tools and treatment techniques at any point in the rehabilitation process that can be used to accomplish immediate goals. If function is the end goal, then early attention to neuromuscular control, movement, and mechanics must be addressed after range of motion and effusion control and prior to/simultaneous with strengthening. Patella fracture as a result of rehabilitation should be an avoidable complication of ACL reconstruction. Accelerated programs that emphasize early return to sports activities and incorporate early high-stress exercises must take into account the previous activities of the patient. The patella should be considered at risk in the first 8–12 weeks of rehabilitation. All protocols should take this into account. JOSPT

Patella fracture as a result of rehabilitation should be an avoidable complication of ACL reconstruction.

REFERENCES

1. *Bronner S: Functional rehabilitation of the spine: The lumbopelvis as the key point of control. In: Brownstein B, Bronner S (eds), Functional Movement in Orthopaedic and Sports Physical Therapy—Evaluation, Treatment and Outcomes, pp 165–176. New York: Churchill Livingstone, 1997*
2. *Carangelo RJ, Caputo AE, Langeland RH: Postoperative patella fractures after autogenous patellar tendon harvesting for anterior cruciate ligament reconstruction. Presented at the Eastern Orthopaedic Conference, Bermuda, October, 1994*
3. *Christen B, Jakob R: Fractures associated with patellar ligament grafts on cruciate ligament surgery. J Bone Joint Surg 74B:617–619, 1992*
4. *Daluga D, Johnson C, Bach B: Primary bone grafting following graft procurement for anterior cruciate ligament insufficiency. Arthroscopy 6:205–208, 1990*
5. *De Carlo MS, Sell KE, Shelbourne KD, Klootwyk TE: Current concepts on accelerated ACL rehabilitation. J Sport Rehabil 3:304–318, 1994*
6. *Friis EA, Cooke FW, McQueen DA, Henning CE: Effect of bone block removal and patellar prosthesis on stresses in the human patella. Am J Sports Med 22:696–701, 1994*
7. *Fu FH, Woo SL-Y, Irrgang JJ: Current concepts for rehabilitation following anterior cruciate ligament reconstruction. J Orthop Sports Phys Ther 15:270–278, 1992*
8. *Johansson H, Sjölander P, Sojka P: Receptors in the knee joint ligaments and their role in the biomechanics of the joint. Crit Rev Biomed Eng 18:341–367, 1991*
9. *Johansson R, Magnusson M: Human postural dynamics. Crit Rev Biomed Eng 18:413–435, 1991*
10. *Lambert KL, Cunningham RR: Anatomic substitution of the ruptured ACL using a vascularized patellar tendon graft with interference fixation. In: Feagin JA (ed), The Crucial Ligaments (1st Ed), pp 401–408. New York: Churchill Livingstone, 1988*
11. *Mangine RE: Kentucky Rehab Service, Fort Mitchell, KY (personal communication)*
12. *McCarroll JR: Fracture of the patella during a golf swing following reconstruction of the anterior cruciate ligament. A case report. Am J Sport Med 11:26–27, 1983*
13. *McCarthy MR, Buxton BP, Hiller WDB, Doyle JR, Yamada D: Current protocols and procedures for anterior cruciate ligament reconstruction and rehabilitation. J Sport Rehabil 3:204–217, 1994*
14. *Mulder T, Nienhuis B, Pauwels J: The assessment of motor recovery: A new look at an old problem. J Electromyogr Kinesiol 6:137–145, 1996*

15. *Ohkoshi Y, Yasuda K, Kaneda K, Wada T, Yamanaka M: Biomechanical analysis of rehabilitation in the standing position. Am J Sports Med 19:605–609, 1991*
16. *Palmitier RA, An K-N, Scott SG, Chao EYS: Kinetic chain exercise in knee rehabilitation. Sports Med 11:402–413, 1991*
17. *Parker MG: Biomechanical and histological concepts in the rehabilitation of patients with anterior cruciate reconstructions. J Orthop Sports Phys Ther 20:44–49, 1994*
18. *Shelbourne KD, Nitz PA: Accelerated rehabilitation after anterior cruciate ligament reconstruction. Am J Sports Med 18:292–299, 1990*
19. *Steinkamp LA, Dillingham MF, Markel MD, Hill JA, Kaufman KR: Biomechanical considerations in patellofemoral joint rehabilitation. Am J Sports Med 21:438–444, 1993*
20. *Wilk KE, Romaniello WT, Scosia SM, Arrigo CA, Andrews JR: The relationship between subjective knee scores, isokinetic testing, and functional testing in the ACL-reconstructed knee. J Orthop Sports Phys Ther 20:60–73, 1994*